Fig. 1.

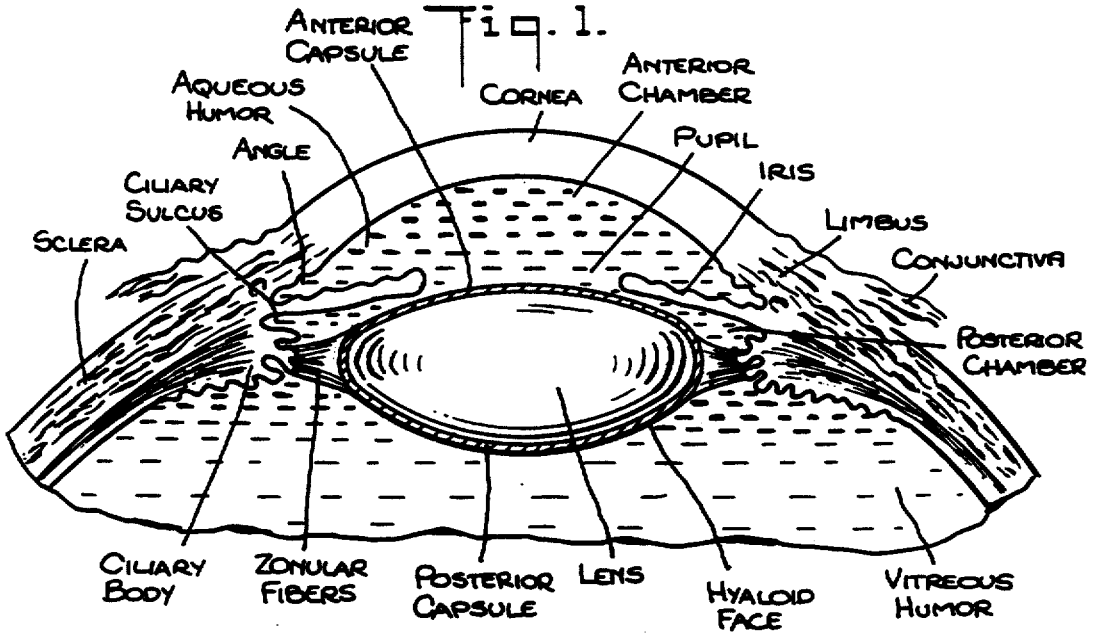
Anterior Capsule
Aqueous Humor
Angle
Ciliary Sulcus
Sclera
Cornea
Anterior Chamber
Pupil
Iris
Limbus
Conjunctiva
Posterior Chamber
Ciliary Body
Zonular Fibers
Posterior Capsule
Lens
Hyaloid Face
Vitreous Humor

Fig. 2.

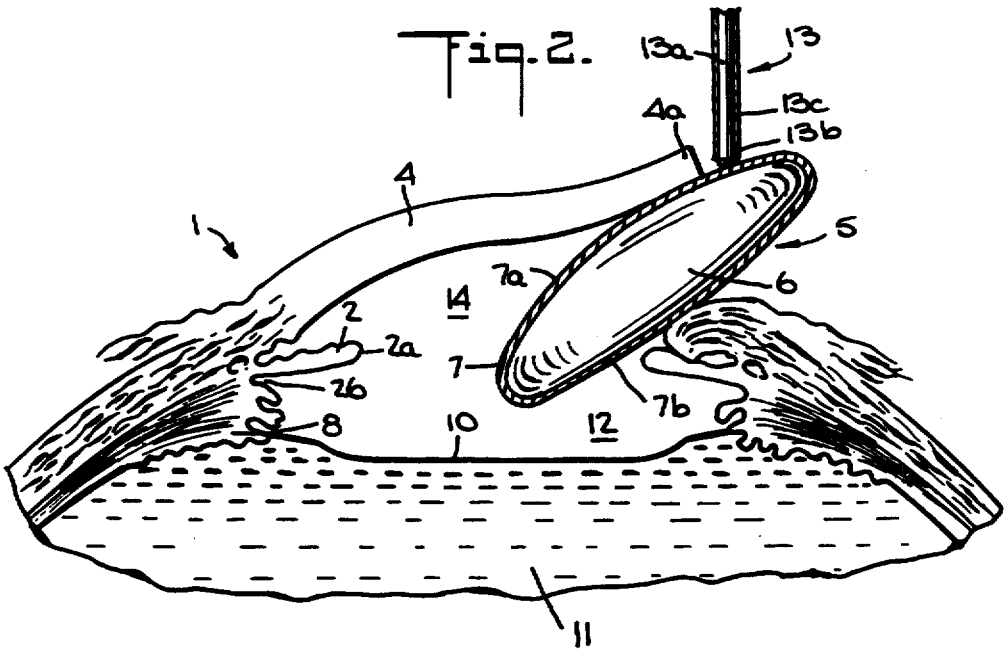
13a
13
13c
13b
4a
4
1
5
6
7a
14
2
2a
7
2b
7b
8
10
12
11