FIG. 1

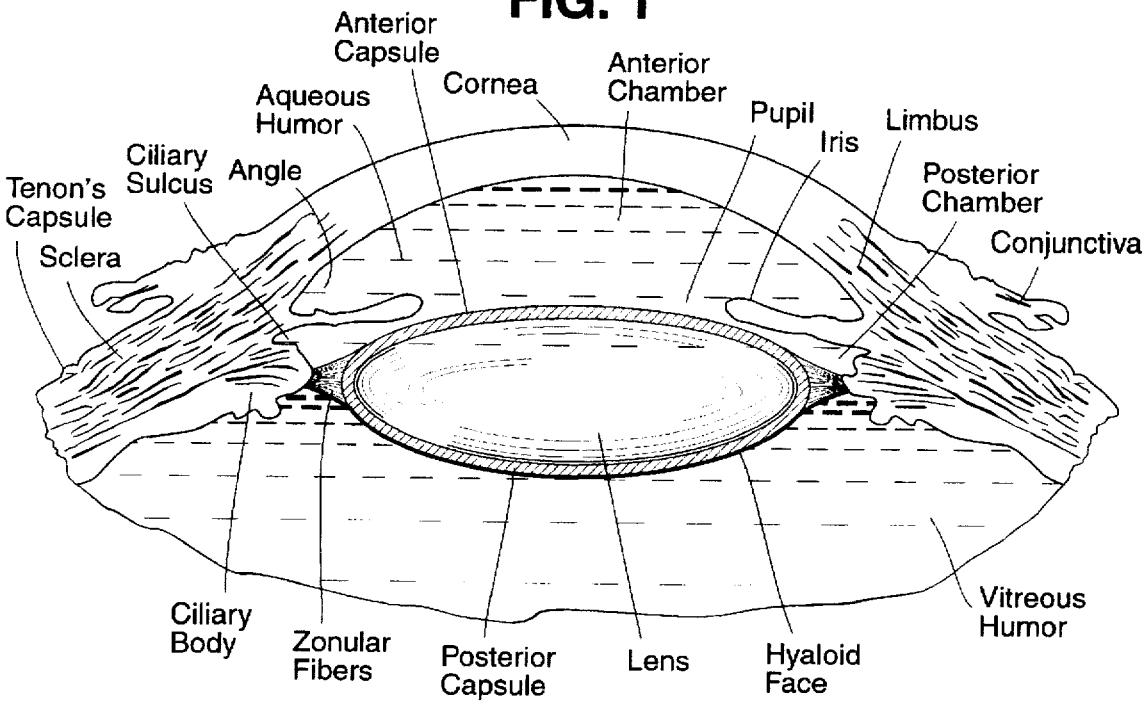
Anterior Capsule
Cornea
Anterior Chamber
Aqueous Humor
Pupil
Iris
Limbus
Ciliary Sulcus
Angle
Posterior Chamber
Tenon's Capsule
Conjunctiva
Sclera
Ciliary Body
Zonular Fibers
Posterior Capsule
Lens
Hyaloid Face
Vitreous Humor

FIG. 2

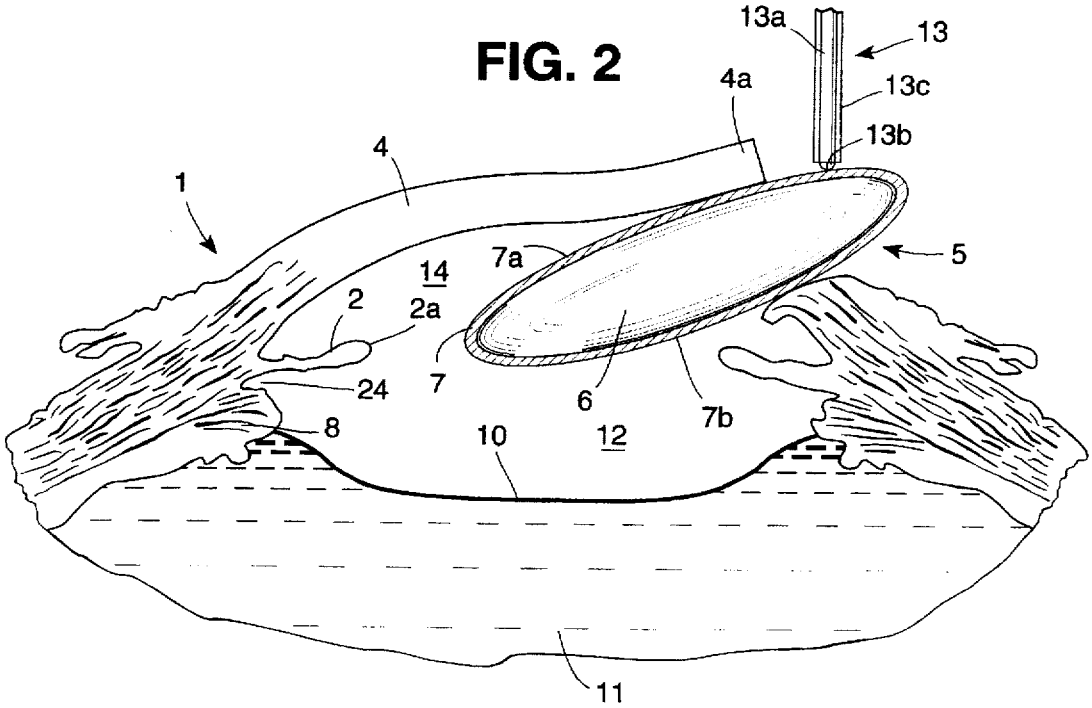
13a
13
4a
13c
13b
4
1
5
7a
14
2
2a
24
7
6
7b
8
10
12
11