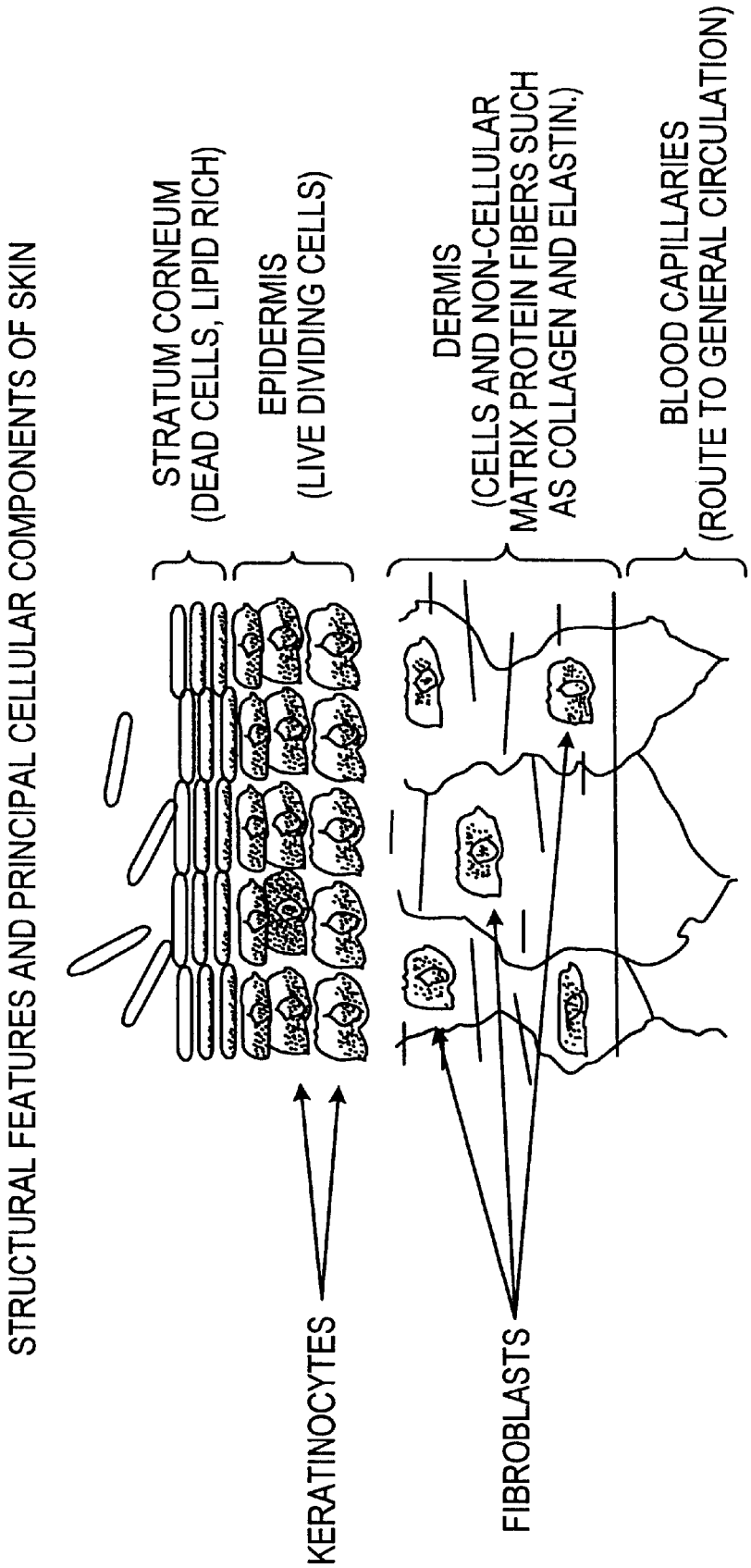
STRUCTURAL FEATURES AND PRINCIPAL CELLULAR COMPONENTS OF SKIN
STRATUM CORNEUM
(DEAD CELLS, LIPID RICH)
EPIDERMIS
(LIVE DIVIDING CELLS)
DERMIS
(CELLS AND NON-CELLULAR
MATRIX PROTEIN FIBERS SUCH
AS COLLAGEN AND ELASTIN.)
BLOOD CAPILLARIES
(ROUTE TO GENERAL CIRCULATION)
KERATINOCYTES
FIBROBLASTS

FIG. 1