FIG. 1

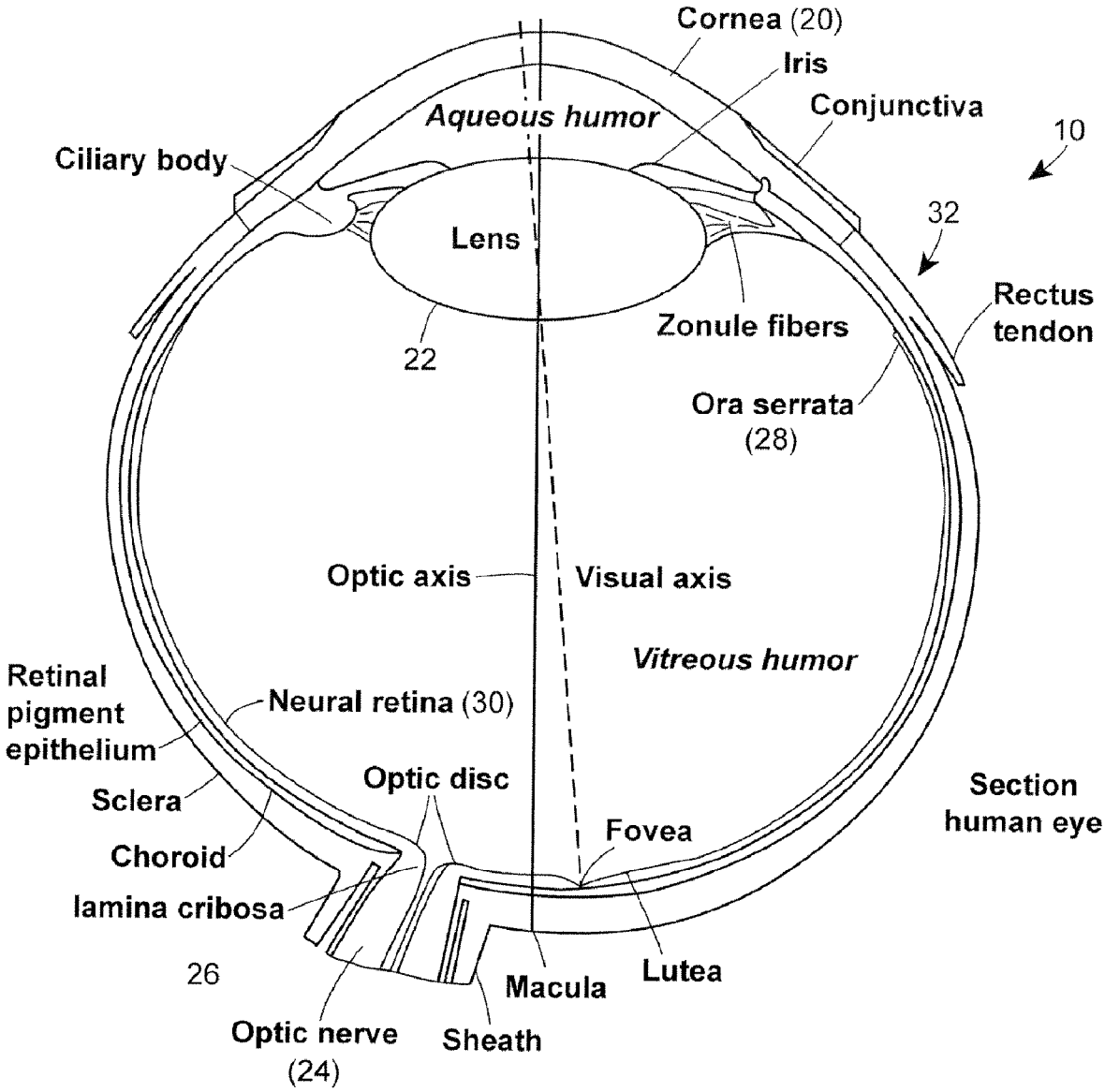
Cornea (20)
Iris
Conjunctiva
Aqueous humor
10
Ciliary body
32
Lens
Rectus tendon
Zonule fibers
22
Ora serrata (28)
Optic axis
Visual axis
Vitreous humor
Retinal pigment epithelium
Neural retina (30)
Sclera
Optic disc
Section human eye
Fovea
Choroid
lamina cribosa
26
Lutea
Macula
Optic nerve (24)
Sheath